

RECONSTRUCTIVE STRATEGIES IN SOFT TISSUE COVERAGE OF LEG – A PROSPECTIVE DESCRIPTIVE STUDY

S. Anuradha¹, V. Jeyakodish², S. Aram³

¹Assistant Professor, Department of Plastic Surgery, Madurai Medical College, Tamilnadu, India.

²Associate Professor, Department of Plastic Surgery, Madurai Medical College, Tamilnadu, India.

³Associate Professor, Department of Plastic Surgery, Madurai Medical College, Tamilnadu, India.

Received : 09/11/2023
Received in revised form : 01/01/2024
Accepted : 17/01/2024

Keywords:

Lower extremities, Leg defects, Soft tissue coverage, Partial flap necrosis, Reconstructive strategies.

Corresponding Author:

Dr. S. Aram,

Email: draramplastic@yahoo.co.in.

DOI: 10.47009/jamp.2024.6.1.315

Source of Support: Nil,

Conflict of Interest: None declared

Int J Acad Med Pharm
2024; 6 (1); 1586-1591



Abstract

Background: The lower extremities are crucial for supporting body weight and activities; however, injuries from industrial accidents, road traffic, warfare, and mines cause long-term disability. This study aimed to evaluate different reconstructive options for managing leg defects and develop an algorithm for soft tissue coverage in different leg parts. **Material & Methods:** This prospective descriptive study was conducted on 50 patients with post-traumatic leg defects in the Department of Plastic and Reconstructive Surgery of Thanjavur Medical College between January 2009 and December 2010. Clinical examinations were conducted to rule out other injuries and assess defect size, presence of exposed structures, wound contamination, and surrounding skin conditions. Patients were evaluated on postoperative 1st, 5th, 10th, 15th and 60th postoperative days. **Results:** The study involved patients aged 5–64 years, with 36% aged 20-30. Most were male, and the leg's most commonly affected region was the lower third. 82% (n=41) of the patients had an exposed tibia with either a fracture of the tibia or a fracture of both bones. The mean hospitalisation duration was 41.74 days (12–75 days). 30% of the patients experienced complications, and the most common complications were partial flap necrosis and wound dehiscence in 8% of the patients. Patient satisfaction was the highest for patients who underwent fasciocutaneous flaps, as 60% felt the reconstruction was good. **Conclusion:** Early debridement and the involvement of the plastic surgeon from the day of injury are important to facilitate early reconstruction, enabling the patient to return to work early.

INTRODUCTION

Since our ancestors began walking upright, the leg has become crucial for supporting body weight and enabling various other activities. However, the lower extremities have been the subject of numerous injuries, including industrial accidents, road traffic, warfare, mines, and terrorist attacks, highlighting the need for improved health and safety measures. WHO estimates that 100% of severe, 50% of moderate and 10% of mildly injured persons need long-term rehabilitation services.^[1] Hospital-based studies reveal that disabilities persist for a long time, with the mean time taken to return to work ranging from 42 months to 120 months.^[2,3] Census 2001 and the National Sample Survey Organization estimate that nearly 2% of the Indian population is disabled.^[4] Injuries are responsible for nearly one-third of all disabilities, and Road Traffic Injuries contribute to nearly half of them.^[5,6] It is estimated that nearly 3.5 million people in India have a

disability from injuries, with about 2 million being due to Road Traffic-related disability.^[7]

The treatment of high-energy lower extremity trauma with soft tissue and bone injury remains a formidable problem. Treatment requires a team of orthopaedic, vascular, and plastic surgeons. The goal in the treatment of open tibial fractures and lower extremity salvage is to preserve a limb that is more functional than amputation. Reconstructive options for lower-limb defects include skin grafts, local flaps, distant flaps, and free flaps. Microsurgical techniques have revolutionised the field and salvable unsalvageable defects. Newer techniques, such as perforator flaps and neurocutaneous flaps, resurgence interest.^[8,9] However, selection criteria are not well established and are a matter of personal judgment. Limb reconstruction is a complex process that involves evolving protocols and evidence-based guidelines.

Aim

This study aimed to evaluate different reconstructive options for managing leg defects and develop an

algorithm for soft tissue coverage in different leg parts.

MATERIALS AND METHODS

This prospective descriptive study was conducted on 50 patients with post-traumatic leg defects in the Department of Plastic and Reconstructive Surgery of Thanjavur Medical College between January 2009 and December 2010. Ethical committee approval and informed consent were obtained before the study initiation.

Inclusion Criteria

All patients with post-traumatic defects of the leg, including the non-weight-bearing heel, which required a soft tissue cover, were included.

Exclusion Criteria

Patients with degloving injuries, arterial injury, head injury, abdominal injury, thoracic injury, bony injuries elsewhere, brachial plexus injuries, patients who were not willing to participate, and patients for whom skin graft was planned were excluded.

Patients were assessed clinically and included in the study according to the inclusion and exclusion criteria. Patients were admitted to the trauma ward and treated with first aid. The patients were resuscitated to minimise bleeding and restore the airway. A detailed history was obtained, including the injury mechanism, time since injury, and neurological deficits. Clinical examinations were conducted to rule out other injuries and assess defect size, presence of exposed structures, wound contamination, and surrounding skin conditions. Laboratory investigations were conducted for surgical fitness, and X-ray and Doppler studies were used to identify and classify fractures.

Patients were admitted for wound toilet and debridement, and skeletal stability was achieved using external fixators, plates, or K-wires. Wound swabs were sent for culture and sensitivity testing, and systemic antimicrobials were used to control the infection. Wounds were dressed daily with a saline dressing, and a soft tissue cover was planned once infection-free. The appropriate reconstructive technique was selected based on the site, size, type, local tissue condition, previous surgical procedures, planned procedures, and the patient's general condition.

All patients received postoperative care, including proper antibiotic therapy, analgesics in the postoperative period, elevation of the limb to prevent oedema, and monitoring of flap colour, temperature, and capillary refill. The first Look skin graft dressing was performed on the 5th postoperative. Assisted ambulation was allowed whenever possible at the end of the 2nd postoperative day. Dependable weight bearing was allowed at the end of the 7th postoperative day, depending on the presence of bone fractures and the method of bone fixation. The sutures were removed on the 10th postoperative day, and the patients were

transferred back to the orthopaedic surgeon for further treatment.

Patients were evaluated on postoperative 1st, 5th, 10th, 15th and 60th postoperative days. Evaluation parameters included viability and stability of the flap, use of the skin graft for secondary defects, presence of pain, ulceration, functional deficit, hospital stay, and patient satisfaction with the reconstruction. On the 30th day, the patients were asked to grade the reconstruction subjectively regarding functionality, return to work, and aesthetic appeal.

Data were collected in a pro forma, including epidemiological data, clinical data, wound area measurements, and operative surgical information. The obtained data were subjected to simple statistical analysis to determine and analyse the various reconstructive options.

RESULTS

The ages of the patients ranged from 5 to 64 years. 36% (n=18) of the patients were between 20 and 30 years old, and 20% (n=10) were between 31 and 40. The percentages of male and female patients who participated were 82% and 18%, respectively. The male-to-female ratio was 4.5:1. [Table 1]

62% of the patients had involvement of the right leg (62%, n=31), and the most commonly involved region was the lower third of the leg, which included the non-weight-bearing heel, accounting for 52% of the patients. Defects in the upper and middle thirds amounted to 22% (n=11) and 24% (n=12), respectively. [Table 2]

For the flap cover, 82% (n=41) of the patients had an exposed tibia with either fracture of the tibia or fracture of both bones (Gustillo Anderson classification IIIb), 16% (n=8) of the patients had exposed tendon Achilles, and one patient required flap cover due to an exposed plate for fracture of the lateral malleolus. The size of the defects revealed that 36% (n=18) had small defects, 60% (n=30) had moderate defects, and 6% (n=3) had large defects. The mean size of the defect was 40.1 cm², and the defects ranged from 4 cm² to 120 cm². [Table 3]

Neuro fasciocutaneous flaps were used to reconstruct lower third defects, followed by fasciocutaneous flaps for the upper and middle third. Random pattern flaps were used in 14% of the patients, with 42% used for upper and middle third defects. Muscle flaps were used in 10% of patients, with 80% used for upper-third defects and one for lower-third defects. Perforator-based propeller flaps were used in 6% of patients, with two patients having lower third and one with middle third defects. Cross-leg flaps were required in 4% of the patients. One patient underwent free microvascular tissue transfer for leg defect reconstructions.

Random flaps included advancement (29%), bipedicle (42%), and rotation flaps (29%). The average size of the defects reconstructed using local

flaps was 18.7 cm². Fasciocutaneous flaps included superiorly-based (47%), inferiorly-based (47%), and double flaps (6%). The average size of the defects reconstructed using fasciocutaneous flaps was 55.3 cm².

Muscle flaps included the gastrocnemius (80%) and the abductor hallucis (20%). The average reconstruction size using local flaps was 18.7 cm². Neurofasciocutaneous flaps included reverse sural (70%), reverse peroneal (12%), and reverse saphenous flaps (18%). The average size of the defects reconstructed using local flaps was 37.7 cm². [Table 4]

44% of the small-sized defects were reconstructed using regional flaps, whereas the remaining 56% could be reconstructed with a local flap. Of the medium-sized defects, 55% were reconstructed with local flaps, whereas the remaining 45% required a regional flap. None of the small or medium-sized defects required distant or free flaps. All three large defects required a regional or free flap. [Table 5 and Figure 1]

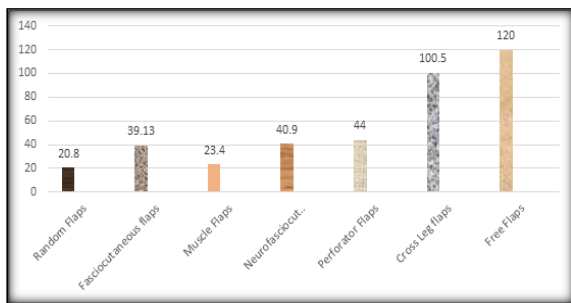


Figure 1: Average size of defect and flap options

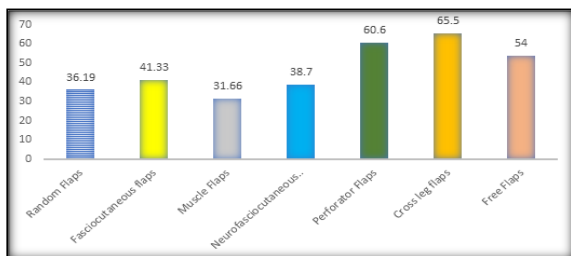


Figure 2: Relationship between duration of hospitalisation and flap options

The mean hospitalisation duration was 41.74 days (12–75 days). Distant and free flaps required longer hospital stays, 65.5 and 54 days, respectively. Random pattern flaps required the least time, with an average hospitalisation duration of 36.19 days. 30% of patients experienced complications; the most common complications were partial flap necrosis and wound dehiscence in 8%. [Figure 2]

The complications revealed that fasciocutaneous flaps had no incidence of major complications, and neurofasciocutaneous flaps had a complication rate of 17% for major complications. One patient who underwent free-flap surgery experienced skin graft loss, which required re-grafting. 42% (n=21) of the patients rated the reconstruction as good, 46% (n=23) rated the reconstruction as fair, and 10% (n=5) of the study population felt that the reconstruction they underwent was poor in terms of functionality, return to work, and aesthetic appearance. [Table 6]

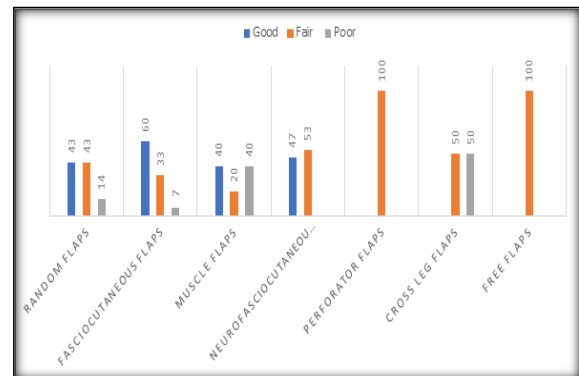


Figure 3: Relationship between flap options and patient satisfaction

Patient satisfaction was highest for patients who underwent fasciocutaneous flaps, as 60% of the patients felt that the reconstruction was good, while it was the least for patients who underwent cross-leg flaps, where 50% felt that the reconstruction was poor. [Figure 3]

Table 1: Age and sex distribution of the study population

Age group	Male	Female
<20	3	3
20-30	14	4
31-40	10	0
41-50	5	2
51-60	7	0
>60	2	0

Table 2: Side and site distribution of the study population

Side	Site		
	Upper 3rd	Middle 3rd	Lower 3rd
Right	8	4	19
Left	3	8	8

Table 3: Distribution of indications for flap cover and size

	Frequency	Percentage

Indications for flap cover	Exposed tibia	41	82
	Exposed tendon Achilles	8	16
	Exposed implants	1	2
Size	Small	18	36
	Medium	30	59
	Large	3	6

Table 4: Type of flaps in the study

Flaps		Patients	The average size of the defect
Local random flaps	Advancement flaps	2	9
	Bipedicled flaps	3	33.3
	Rotation flaps	2	14
	Total	7	18.7
Fasciocutaneous flaps	Superiorly based flap	7	35.7
	Inferiorly based flap	7	42.4
	Double transposition flap	1	88
	Total	15	55.3
Muscle flaps	Gastrocnemius flap	4	80
	Abductor hallucis flap	1	20
Neurofasciocutaneous flaps	Reverse sural flap	11	70
	Reverse peroneal flap	2	12
	Reverse saphenous flap	3	18

Table 5: Relationship between size of defect and flap options

Size	Local flaps	Regional flaps	Distant and free flaps	Total
Small	10	8	-	18
Medium	16	13	-	29
Large	-	-	3	3
Total	26	21	3	50

Table 6: Flap options and complications

	Complications	
	Minor	Major
Random flaps	-	-
Fasciocutaneous flap	4	-
Muscle flaps	-	-
Neurofasciocutaneous flaps	3	3
Perforator flaps	1	-
Cross leg flaps	-	-
Free flaps	-	1
Total	8	4

DISCUSSION

This was a prospective study of 50 patients who underwent soft tissue reconstruction during the study period. The majority of the patients were male with a male-to-female ratio of 4.5:1 and the mean age of the patients who required reconstruction was 41.74 years, and 48% of the patients fell in the age group of 20 to 40 years, which is along the national trends in road traffic accident mortality and morbidity.^[7] Hence, the reconstructive needs are the most for the most productive age group of the population, and early return to work and restoration of near-normal functionality should be aimed at any reconstruction of the lower extremity.

In our study, the lower third of the leg was the most commonly involved (54%), and the exposed tibia was the most common indication for surgery in the study population, corroborated by other epidemiological data.^[10,11] Lower third leg defects have always been considered to be the domain of free flaps; however, recent innovations have challenged this; with the development of freestyle perforator-based propeller flaps and

neurofasciocutaneous flaps, non-microsurgical reconstruction of such defects has become feasible. This is of special significance in a resource-challenged centre like ours.

In our study, we attempted to explore reconstructive strategies for lower-third reconstructions. A large number of authors suggests early consultation for soft tissue reconstruction and immediate reconstruction, but due to the protocol in our institute where these patients are admitted by orthopaedic surgeons and the initial treatment is provided by orthopaedic surgeons by the time a plastic surgery opinion is sought, the infection has settled in in the infection has to be tackled before reconstruction of the soft tissue. No immediate bony reconstruction was performed, and all patients who required bone reconstruction underwent the procedure in the subsequent stages.

In our study, 94% of the patients had either a small or moderate-sized defect, with only 6% having a large defect. This probably indicates a bias in case selection based on the prevailing reconstructive strategies in our centre, where microsurgical reconstruction is still in the early stages; hence, such larger defects were deferred from inclusion in the

study. All defects classified as large required distant or free flaps; the rest were managed with regional or local flaps. The size of the defect and the centre's experience in microvascular surgery were significant factors in deciding the reconstructive options, which is demonstrated by other authors who operate in similar settings.^[12]

In our study, local random pattern flaps were used in 14% of the patients with excellent results, as none of the flaps had any complications; however, the flaps were restricted to the upper and middle third of the leg, and the average size of the defect reconstructed using these flaps was 20.8sqcm. These flaps are viable options for small defects in the upper third and some in the middle third of the leg. The gastrocnemius muscle flap was used in four patients, and the abductor hallucis muscle flap was used in one patient. Muscle flaps were applied to the upper third of the tibia in 4 cases and the lower third in one case. The muscle was immediately covered with a split-thickness skin graft, and the flap survived in all patients. These results show that muscle flaps are highly reliable and can be used safely to cover defects over different aspects of the leg, especially the upper third. These results are in agreement with other studies.^[13-15]

In our study, 15 (30%) patients were managed using local random pattern fasciocutaneous flaps. 47% of the flaps were proximally based, 47% were inferiorly based, and 6% were double flaps in which two flaps, one of which was based inferiorly and the other was based superiorly. Only four flaps (26% of cases) had minor complications. These results show that local random pattern fasciocutaneous flaps are simple to raise, sensate if based proximally, replace like with like tissue, ideal for small and moderate defects, and do not require unusual surgical skills. A disadvantage of fasciocutaneous flaps is their unsightly donor site; therefore, their use should be avoided in young females. They remain a useful method of skin cover for lower-extremity defects. These results agree with other studies that reported nearly similar complication rates, varying from 12% to 26%.^[16,17]

Chittoria and Mishra reported a much lower complication rate (one flap out of 20 had tip necrosis).^[18] Other studies found that neurofasciocutaneous flaps were the most commonly used reconstructive modality for lower-third-leg defects, with 34% of the 17 used. The study included 11 distally based surals, three superficial peroneals, and two saphenous flaps. 17% of the flaps suffered from major complications such as distal flap necrosis, while 17% suffered minor complications. These results suggest that distally based neurofasciocutaneous flaps could be the main treatment for similar leg defects. This one-stage operation is easy to perform, quick to elevate, and provides a reliable vascular supply without sacrificing major arteries or sensory nerves.^[19,20]

The free latissimus dorsi flap was used in one patient in the present study. Free tissue transfer

offers several advantages, including providing well-vascularised tissue to close cavities or defects, matching existing functional and aesthetic defects, minimising donor morbidity, and being large. However, it is a lengthy procedure requiring a well-trained microvascular team and sophisticated, expensive equipment. A high degree of success requires careful patient selection, as has been reported in other studies. Three patients (6%) underwent freestyle perforator flaps, of which one patient developed a minor complication. They were predominantly used to reconstruct the middle and lower third of the leg. Our experience shows that local perforator flaps may provide better aesthetic results for the coverage of a defect, as the adjacent skin has similar texture, thickness, and colour. A disadvantage of the freestyle perforator flaps is that they are technically challenging and need to be experienced in using the handheld Doppler.^[21]

Our study found that the cross leg and free flaps had the longest average hospitalisation duration, followed by perforator flaps and muscle and random pattern flaps. The simplest reconstruction method is faster for patient recovery, but not all defects should be reconstructed with the simplest option. Neurofasciocutaneous flaps had the highest incidence of complications (35%), followed by the fasciocutaneous flaps (26%). Major complications occurred in only 8% of the patients in the study. This is in agreement with studies conducted elsewhere. It was shown that patients with soft tissue defects of the lower leg after a traumatic open tibial fracture should be initially treated with a local musculocutaneous flap whenever possible. If the location or size of the defect makes local reconstruction impossible, free flaps remain the only possibility for reconstruction.^[22,23]

Our study found that 88% of the patients were satisfied with their reconstruction, with local flaps having high satisfaction rates and distant flaps having poor satisfaction rates. However, these patients also had more severe injuries. Early identification and education about possible functional outcomes can mentally prepare patients for the long road ahead and improve long-term functional outcomes after difficult reconstructions.^[3]

CONCLUSION

Local random pattern flaps can successfully reconstruct small leg defects, whereas gastrocnemius muscle flaps are reliable for complex defects. Proximally based fasciocutaneous flaps are preferred for middle-third defects, followed by inferiorly based flaps. Free flaps are ideal for local tissues, whereas cross-leg flaps are suitable for large defects. Distally based sural and saphenous neuro fasciocutaneous island flaps are suitable for lateral and medial defects, whereas inferiorly based flaps are recommended for larger distal defects.

In conclusion, we emphasise the importance of early debridement and the involvement of the plastic surgeon from the day of injury to facilitate early reconstruction, enabling the patient to return to work early. Co-operation between orthopaedic and plastic surgeons at the time of primary surgery will preserve potential flap options by avoiding the placement of pins at sites that would endanger a potential flap or restrict its movement.

Limitations

Financial interest

Conflicts of interest

Acknowledgement.

REFERENCES

- World Health Organization Collaborating Centers for Neurotrauma. Prevention, critical care, and rehabilitation of neurotrauma: perspectives and future strategies. Geneva: World Health Organization. 1995.
- Gururaj G, Channabasavanna SM, Das BS, Kaliaperumal VG. Epidemiology of head injury: project report. Bangalore: NIMHANS and KSCST. 1993. <https://nimhans.ac.in/wp-content/uploads/2019/02/Epidemiology-of-Head-Injuries.pdf>
- Francel TJ, Ca VK, Hoopes JE, Manson PN, Yaremchuk MJ. Microvascular soft-tissue transplantation for reconstruction of acute open tibial fractures: Timing of coverage and long-term functional results. *Plast Reconstr Surg* 1992;89. PMID: 1741471.
- National Sample Survey Organization. Disability in India. NSSO 58th round. New Delhi: Ministry of Statistics and Programme Implementation, Government of India, 2003.
- Gururaj G. Injuries in India: A national perspective. In: Burden of disease in India: Equitable development—Healthy future. New Delhi: National Commission on Macroeconomics and Health, Ministry of Health and Family Welfare, Government of India; 2005:325–47.
- Gururaj G. Epidemiology of traumatic brain injuries: Indian scenario. *Neurol Res* 2002; 24:24–8. <https://doi.org/10.1179/016164102101199503>.
- Gururaj G. Road traffic deaths, injuries and disabilities in India: current scenario. *National Med J India*. 2008; 21:14–20. <https://citeseerx.ist.psu.edu/document?repid=rep1&type=pdf&doi=7915e42da0caacf76a359ed2cb779f25b10a54d1>
- Heller L, Kronowitz SJ. Lower extremity reconstruction. *J Surg Oncol* 2006; 94:479–89. <https://doi.org/10.1002/jso.20485>.
- Çeliköz B, Şengezer M, Işık S, Türegün M, Deveci M, Duman H, et al. Subacute reconstruction of lower leg and foot defects due to high velocity-high-energy injuries caused by gunshots, missiles, and land mines: High-Energy Injuries of Lower Leg and Foot. *Microsurgery* 2005; 25:3–15. <https://doi.org/10.1002/micr.20049>.
- Jha N, Srinivasa DK, Roy G, Jagdish S, Minocha RK. Epidemiological study of road traffic accident cases: A study from South India. *Indian J Community Med* 2004; 29:20. https://journals.lww.com/ijcm/Abstract/2004/29010/EPIDEMIOLOGICAL_STUDY_OF_ROAD_TRAFFIC_ACCIDENTS.5.aspx
- Ngim NE, Udosen AM, Ikpeme IA, Ngim OE. Prospective study of limb injuries in Calabar. *Internet J Orthop Surg* 2007;8. <http://ispub.com/IJOS/8/2/3913>.
- Nguyen TA. Soft tissue coverage at the resource-challenged facility. *Clin Orthop Relat Res* 2008; 466:2451–6. <https://doi.org/10.1007/s11999-008-0386-1>.
- Morris DJ, Pribaz JJ. Transtibial transposition of gastrocnemius muscle and musculocutaneous flaps. *Br J Plast Surg* 1992; 45:59–61. [https://doi.org/10.1016/0007-1226\(92\)90118-h](https://doi.org/10.1016/0007-1226(92)90118-h).
- Arnold PG, Mixer RC. Making the most of the gastrocnemius muscles. *Plast Reconstr Surg* 1983; 72:38–48. <https://doi.org/10.1097/00006534-198307000-00010>.
- Schwabegger AH, Shafiqhi M, Gurunluoglu R. Versatility of the abductor hallucis muscle as a conjoined or distally based flap. *J Trauma* 2005; 59:1007–11. <https://doi.org/10.1097/01.ta.0000187967.15840.15>.
- Hallock GG. Distal lower-leg local random fasciocutaneous flap. *Plast Reconstr Surg* 1990; 86:304–11. <https://doi.org/10.1097/00006534-199008000-00018>.
- Georgiadis GM, Behrens FF, Joyce MJ, Earle AS, Simmons AL. Open tibial fractures with severe soft-tissue loss. Limb salvage compared with below-the-knee amputation. *J Bone Joint Surg Am* 1993; 75:1431–41. <https://doi.org/10.2106/00004623-199310000-00003>.
- Chittoria R, Mishra SM. Fasciocutaneous flaps in reconstruction of lower extremity: our experience. *Kathmandu Univ Med J (KUMJ)* 2004;2. PMID: 16388247.
- Noack N, Hartmann B, Kuntscher MV. Measures to prevent complications of distally based neurovascular sural flaps. *Ann Plast Surg* 2006; 57:37–40. <https://doi.org/10.1097/01.sap.0000208946.40714.07>.
- Cavadas PC. Reversed saphenous neurocutaneous island flap: clinical experience and evolution to the posterior tibial perforator-saphenous subcutaneous flap. *Plast Reconstr Surg* 2003; 111:837–9. <https://doi.org/10.1097/01.prs.0000039573.08861.94>.
- Morris SF, Neligan PC, Taylor GI. Freestyle local perforator flap. In: Blondeel PN, Morris SF, Hallock GG, Neligan PC, eds. *Perforator Flaps: Anatomy, Technique and Clinical Applications*. 1st ed. Vol. 2. St. Louis, MO: Quality Medical Publishing; 2006:947–960. <https://www.scirp.org/reference/referencespapers?referenceid=498184>.
- Franken JM, Hupkens P, Spauwen PHM. The treatment of soft-tissue defects of the lower leg after a traumatic open tibial fracture. *Eur J Plast Surg* 2010; 33:129–33. <https://doi.org/10.1007/s00238-010-0405-9>.
- Saleh Y, Waheeb B, Mustafa A, Mahmoud el-Oteif. A Suggested Algorithm for Post-Traumatic Lower Limb Soft Tissue Reconstruction. *Egypt J Plast Reconstr Surg* 2007;31: 87-96. <https://www.semanticscholar.org/paper/A-Suggested-Algorithm-for-Post-traumatic-Lower-Limb-Saleh-Waheeb/71cb727a8393ca946d0913fdcd6006b238c7898c>.